

# Brucellosis

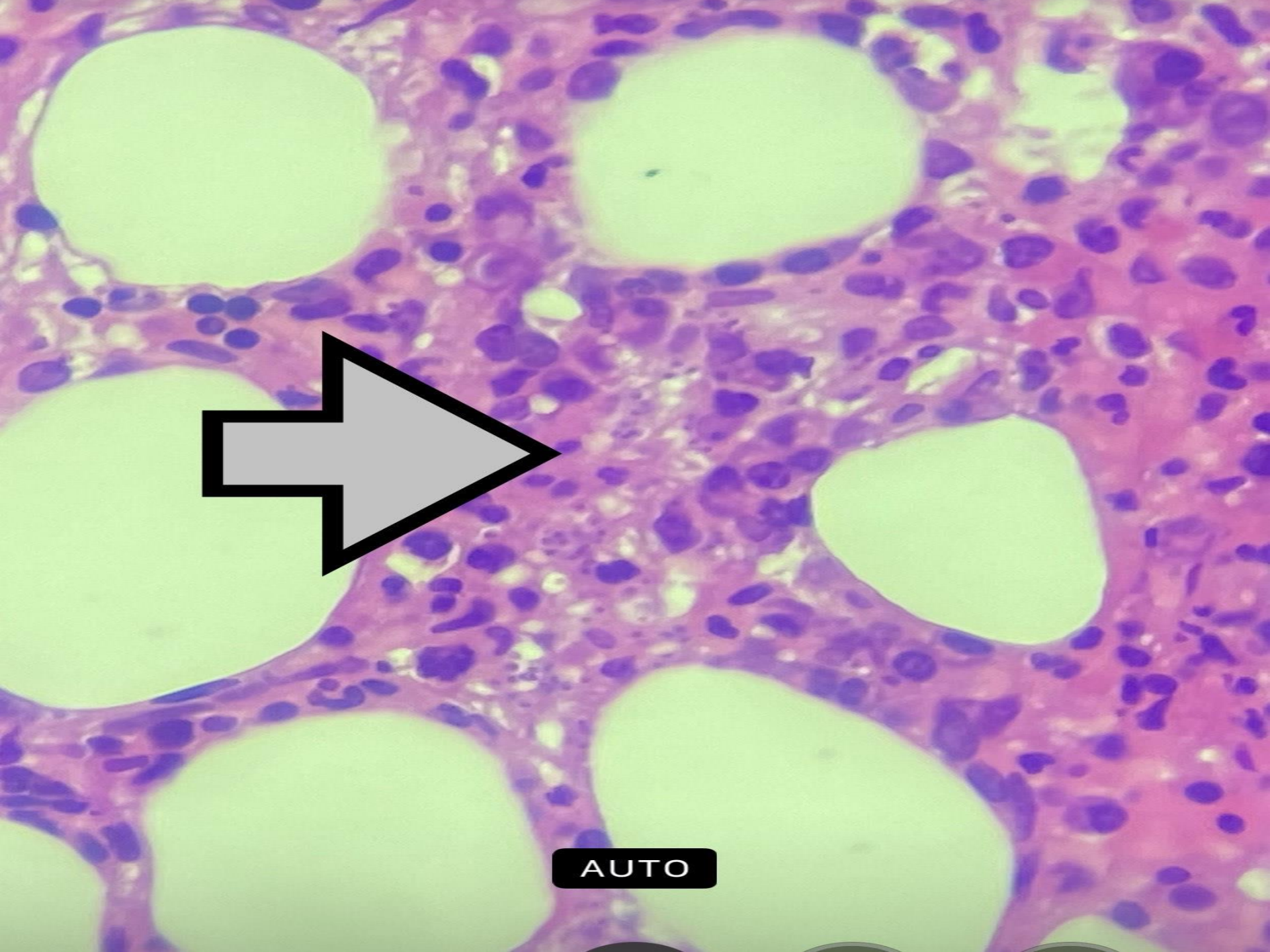
Mansouri D.

MD, MPH, AFSA, DU

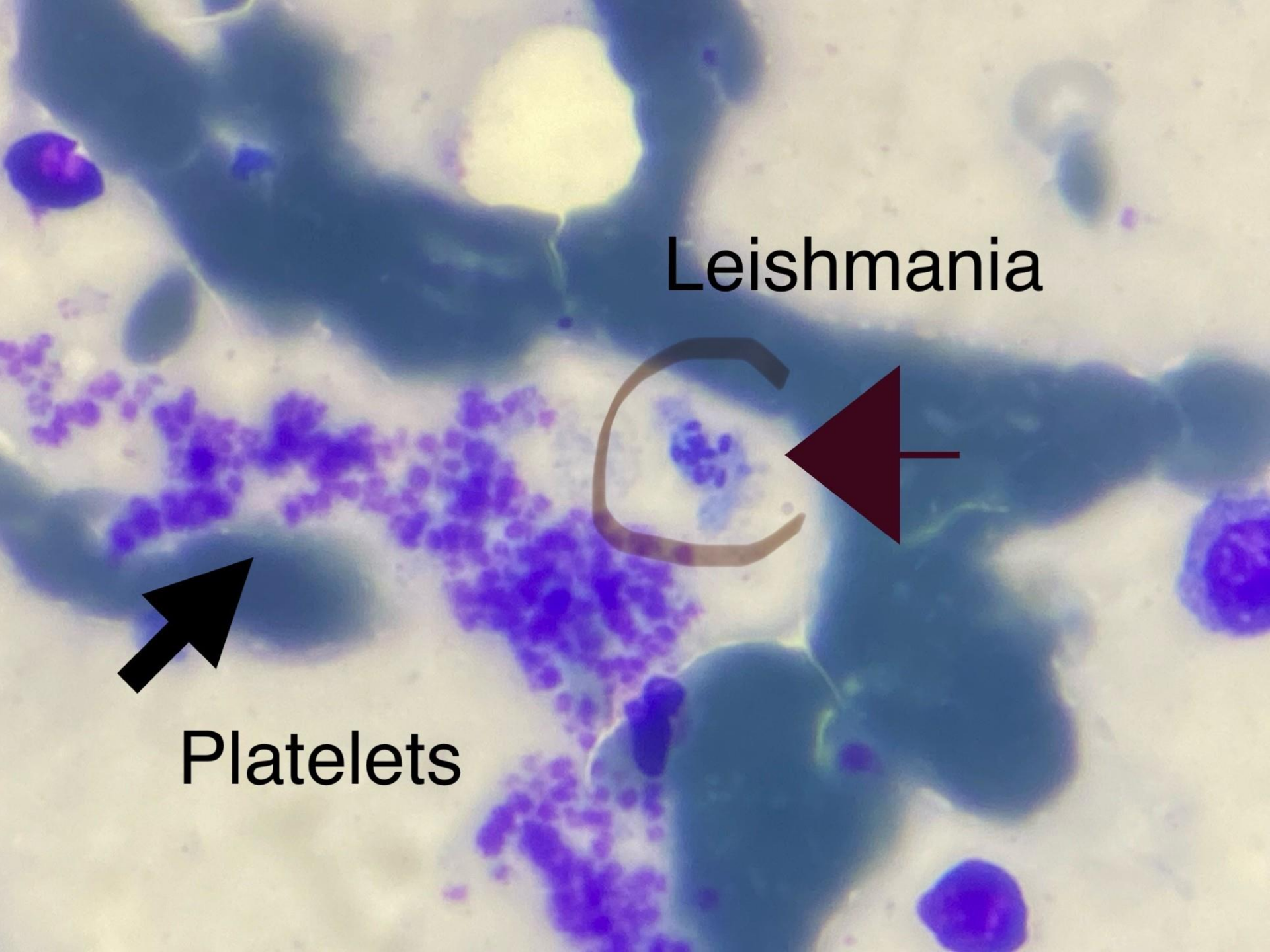
# To treat or Not to treat?

That's The Question.

(Wright: 1/20; Coomb's Wright:1/40;2ME: 1/20)



AUTO




Leishmania

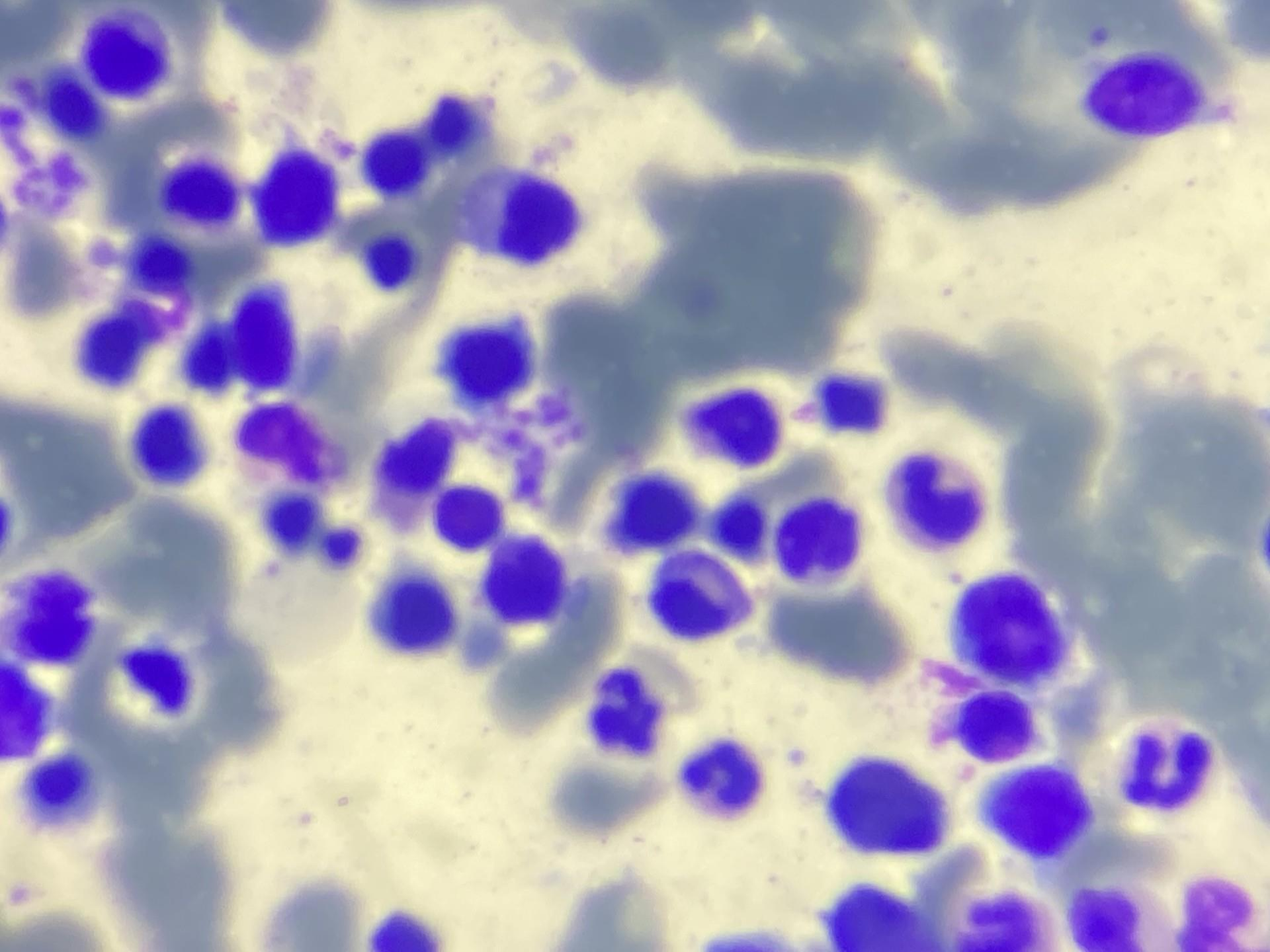


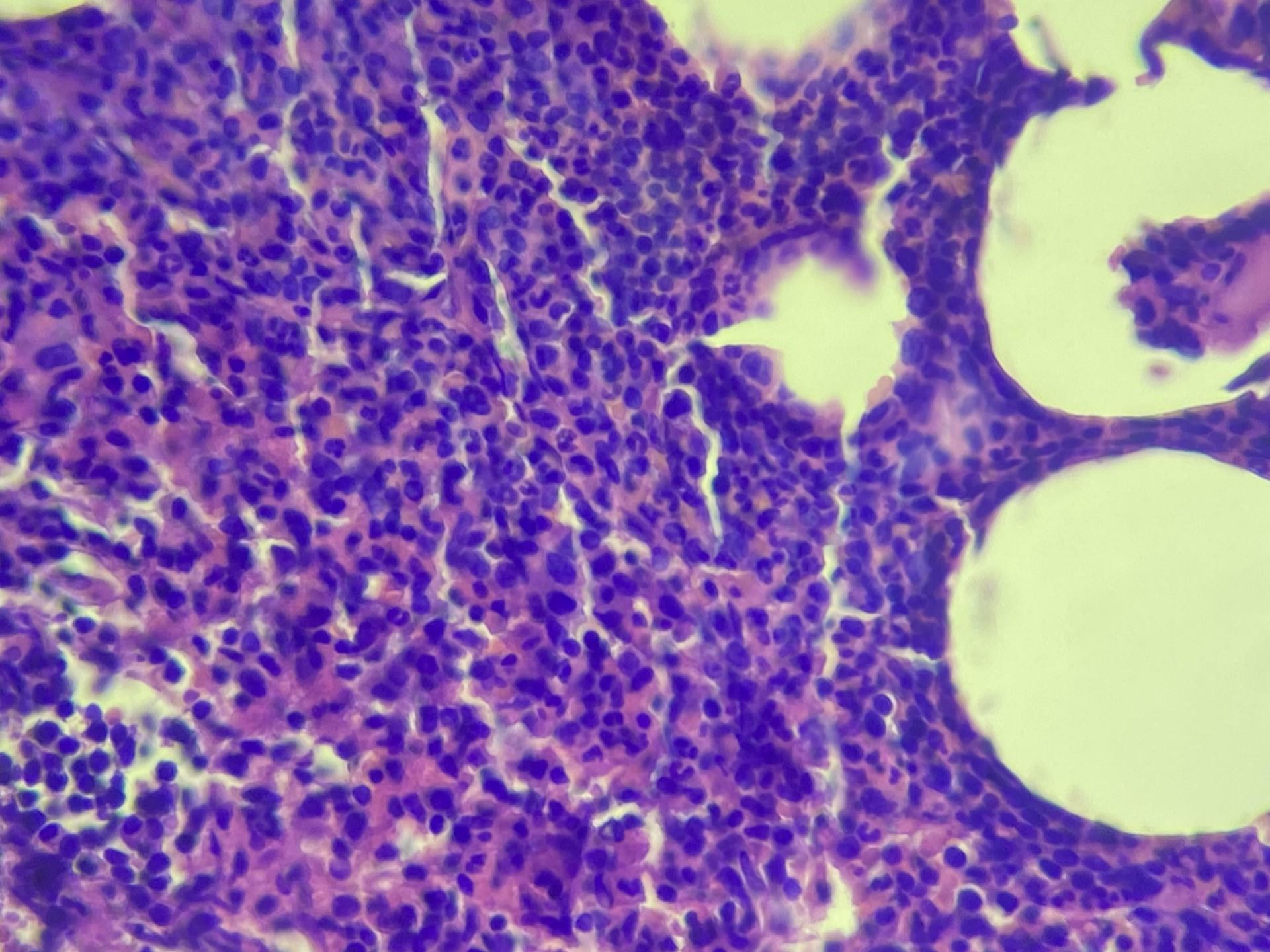
Platelets

Safety pin-shaped  
leishmania

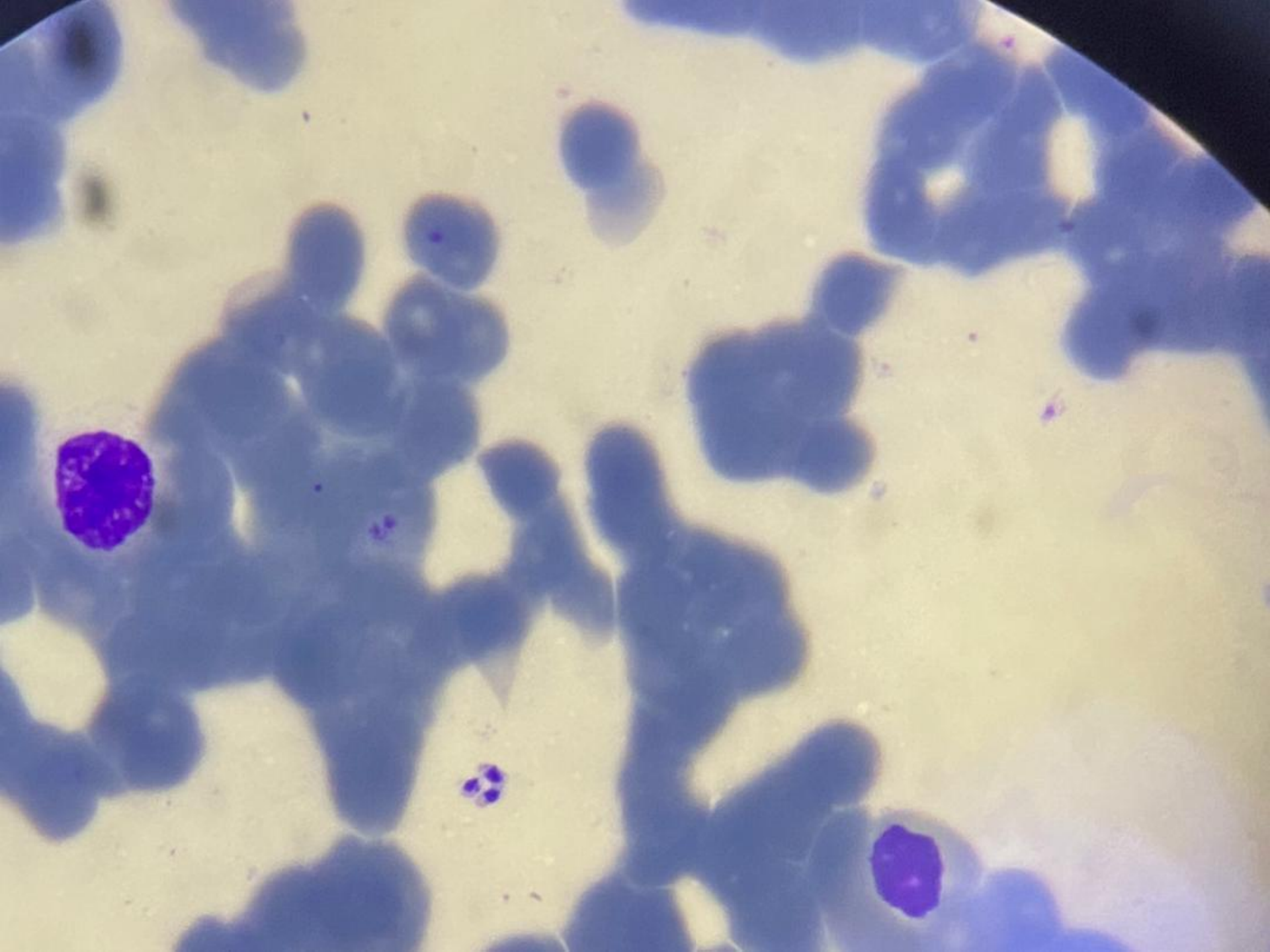


# Discussion









سن : ۶۵ سال	تاریخ پذیرش : ۰۲/۰۲/۰۶	شماره قبض : 02-2900	نام : خانم طیبه شهاب شه میرزادی
تاریخ جواب : ۱۴۰۲/۰۲/۱۰	شماره پاتوبیولوژی : P02-517		پزشک : سرکار خانم دکتر شراره سیفی

**SURGICAL PATHOLOGY REPORT**

**FINAL DIAGNOSIS:**

**Bone marrow aspiration:**

- Presence of intracellular and extracellular **Leishmania** bodies;
- Myeloid preponderance ( M/E ratio: 5/1);
- Lymphoid cells are about 35% and mature;
- Plasmacells make roughly 5% of nucleated cells;
- No increase in blasts.

**Bone marrow biopsy:**

- Hypercellular marrow (80% cellularity) rich in histiocytes with vaguely formed granuloma revealing intracellular amastigotes of **Leishmania**;
- All hematopoietic elements in different stages of maturation are present.

**MICROSCOPIC DESCRIPTION:**

Sections support diagnosis

**CLINICAL INFORMATION:**

65 y/o female with splenomegaly

**GROSS DESCRIPTION:**

Received specimen in formalin and consists of one core of tan bony tissue (3x0.2 cm) and blood clot (1x0.2 cm). After decalcification TS in 2 blocks. Also received 7 unstained aspiration slides.

*دکتر آبتاب درودی*  
**A. Dovudinia, MD, ACP**  
۷۲۲۹

**N. Sadeghi, MD, ACP**

**M. Almasi, MD, ACP**

**R. Aghakhani, MD, ACP**

Date Report Signed: 02/02/10

